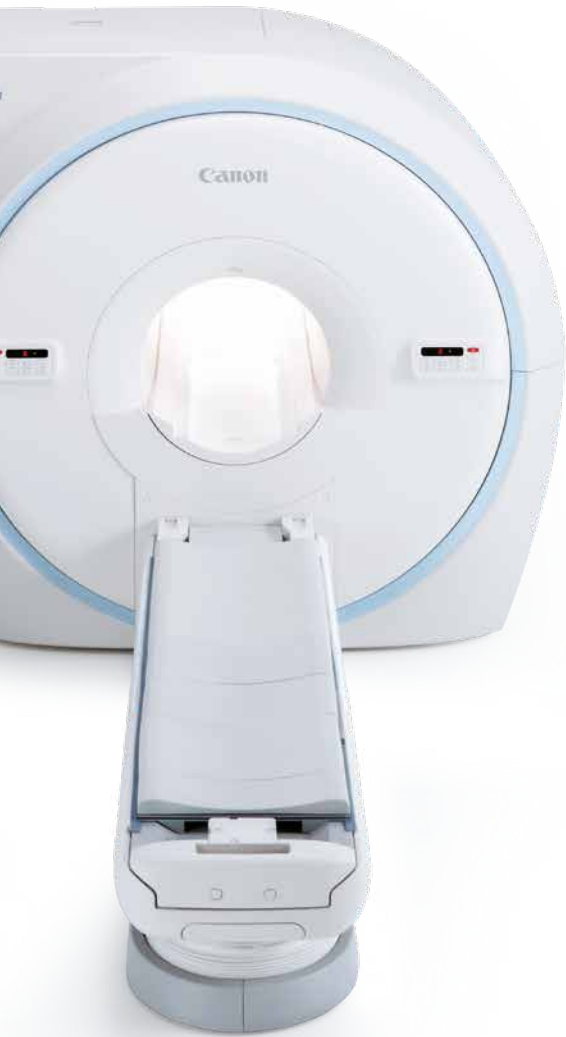


CASE REPORT

Vantage Elan

Clinical Importance of the SPEEDER CX Breast Coil



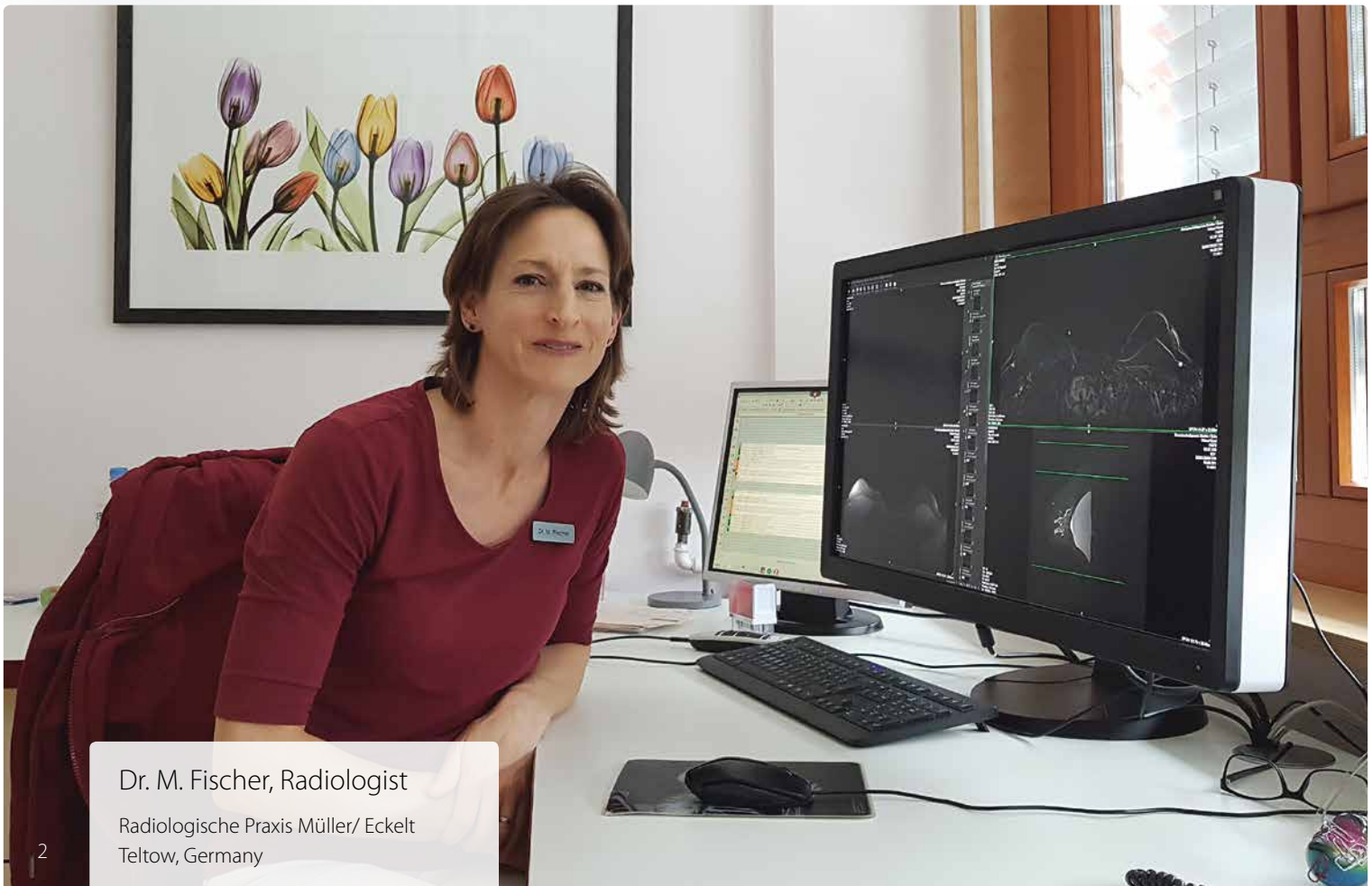

SPEEDER CX Breast Coil

The new breast coil gives us much better spatial resolution. Fat saturation is always homogenous over the entire volume. Images have less motion artefacts due to optimal patient positioning.

There is a perfect contrast in the visualization of implants with the PASTA-technique. Image quality is ideal including the axillary glands in the coronary 2D T1 FE. Even when using sequences with high spatial resolution, the scan times remain short. All sequences perform better than with the old coil.

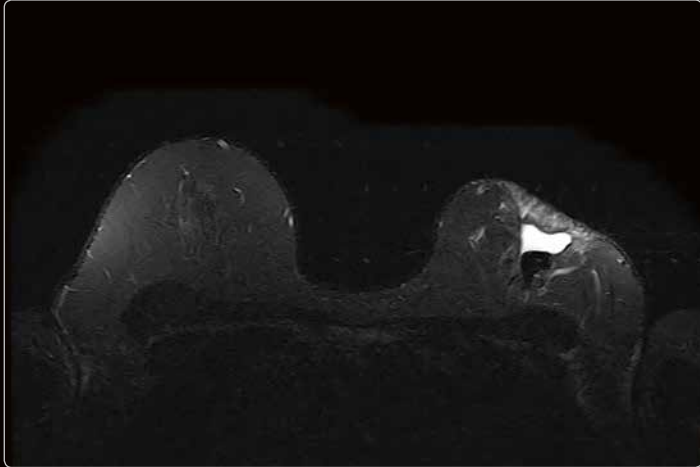
Dr. Fischer, Radiologist



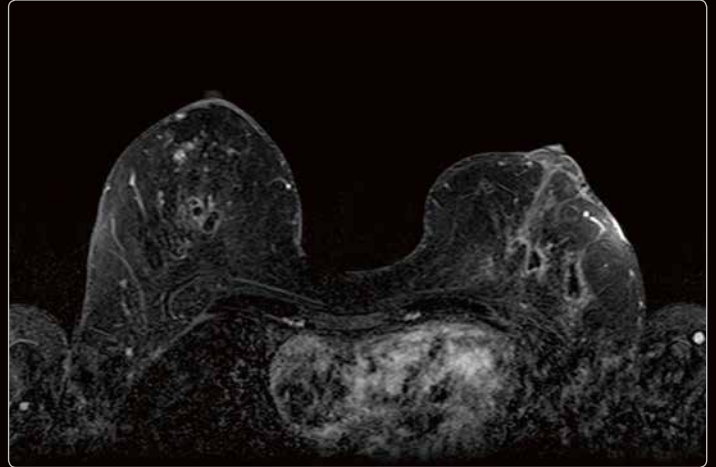
Dr. M. Fischer, Radiologist
Radiologische Praxis Müller/ Eckelt
Teltow, Germany

Carcinoma Follow-Up

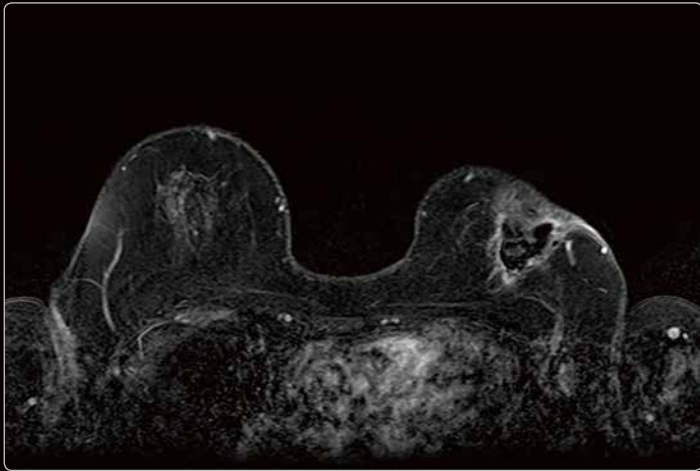
CASE 1



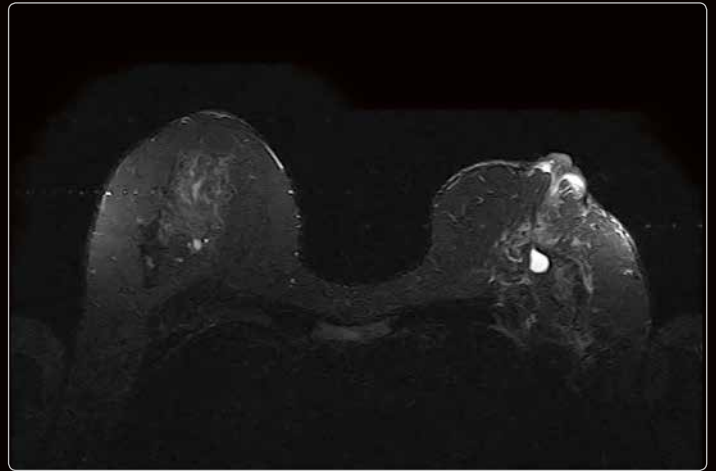
Axial STIR 1.5 mm



Axial 3D T1 Dynamic 1.5 mm



Axial 3D T1 Dynamic 1.5 mm



Axial STIR 1.5 mm

PATIENT HISTORY:

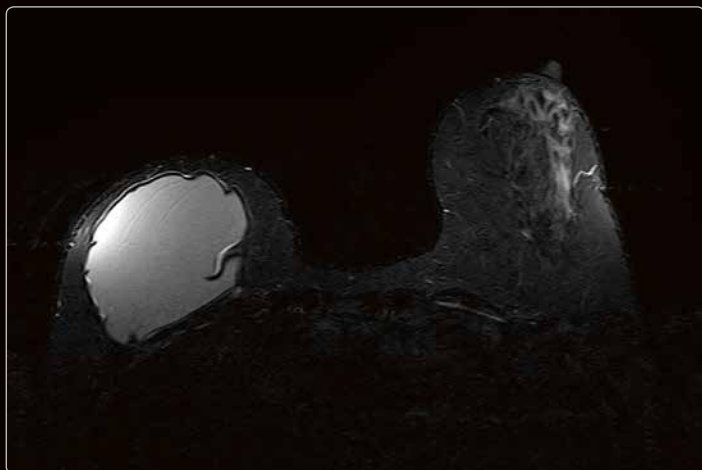
39-year-old female patient with a family history of cancer (three sisters). Mammography and ultrasound were regularly performed. Fast-growing tumor. Biopsy confirmed a highly differentiated invasive lobular carcinoma. Tumor ablation followed by radiotherapy and chemotherapy. Post-operative MR examination to search for further lesions, especially in the right breast.

RESULTS:

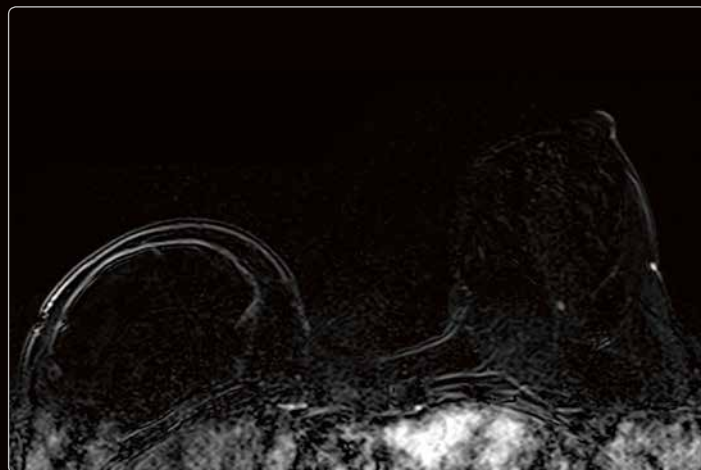
Large postoperative defect in the left breast, some cysts in the right breast. No further suspicious lesions, especially in the right breast, were observed.

Breast Implants

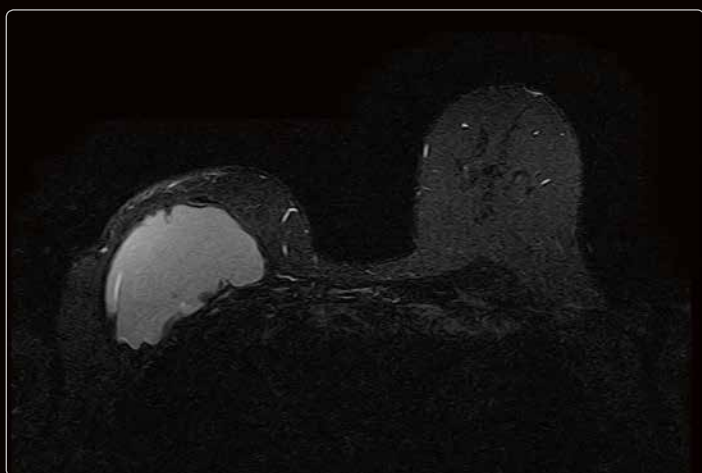
CASE 2



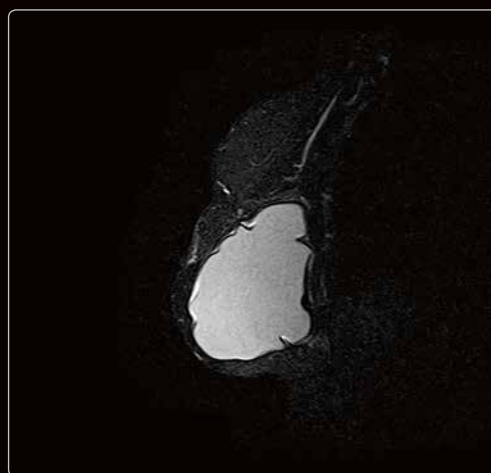Axial STIR 1.5 mm



Axial 3D T1 Dynamic Subtraction 1.5 mm



Axial STIR 1.5 mm



Sagittal STIR 1.5 mm

PATIENT HISTORY:

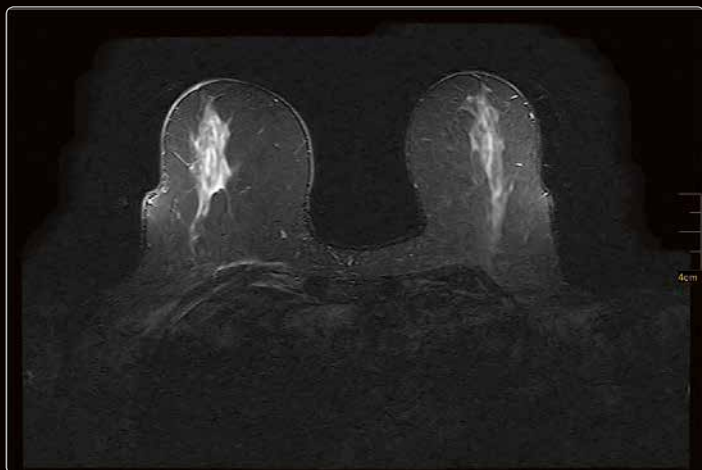
37-year-old female patient, multifocal breast cancer, ablation and breast implant right breast, follow-up because of a lesion in the left breast.

RESULTS:

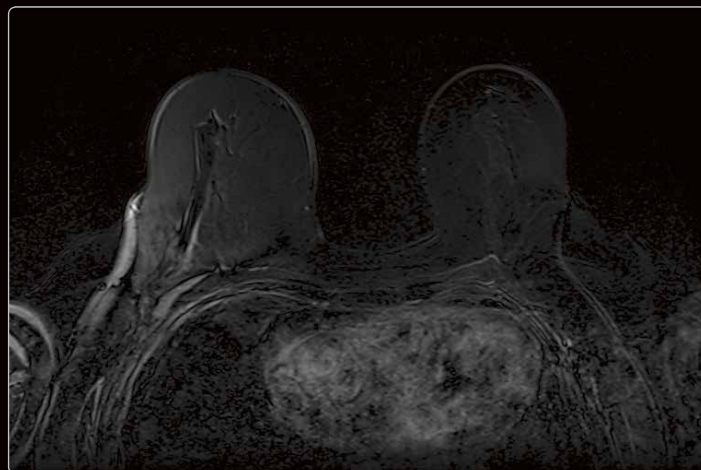
No leakage of the breast implant.
Unchanged lesion in the left breast.

Carcinoma Follow-Up

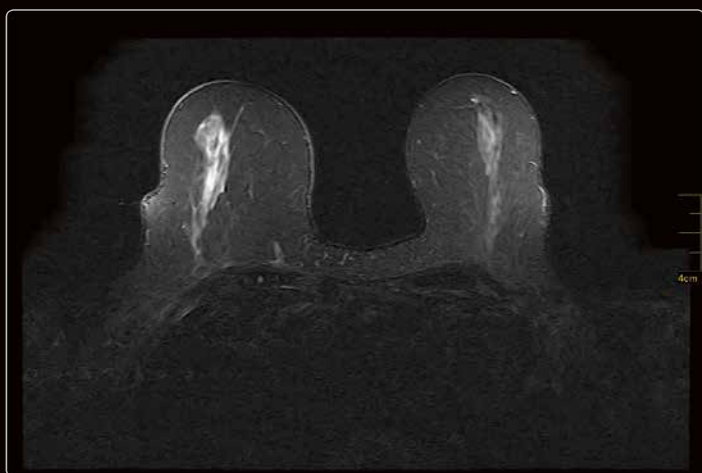
CASE 3



Axial STIR 1.5 mm



Axial 3D T1 Dynamic 1.5 mm



Axial STIR 1.5 mm

PATIENT HISTORY:

72-year-old female patient.

Patient with a history of breast cancer in the right breast. Breast-preserving surgery followed by radiotherapy and chemotherapy.

Recent sonography shows an uncertain finding in the scar region.

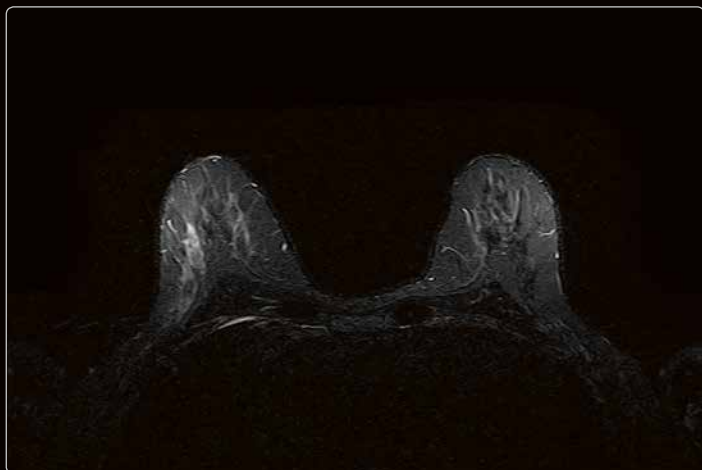
RESULTS:

Some contrast enhancement in the scar region in the upper outer quadrant of the right breast, without showing a primary lesion. A trace of diffuse post-operative fluid is present.

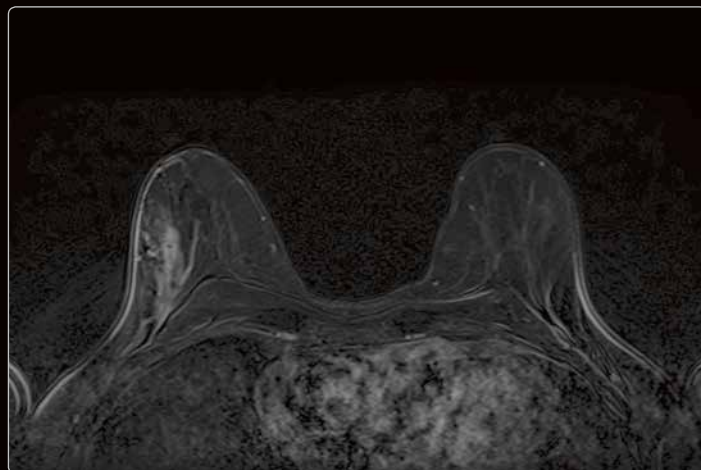
A follow-up examination is advised in 6 months.

Breast Carcinoma

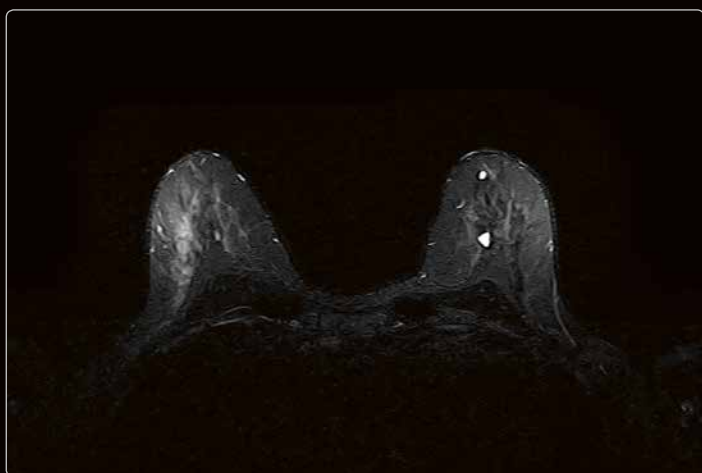
CASE 4



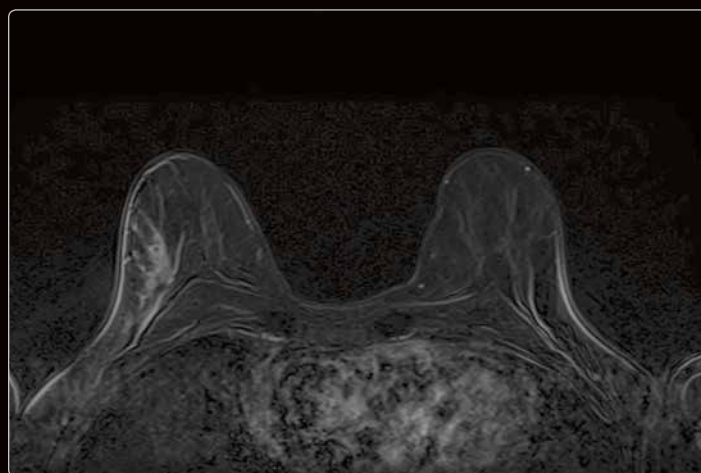
Axial STIR 1.5 mm



Axial 3D T1 Dynamic 1.5 mm



Axial STIR 1.5 mm



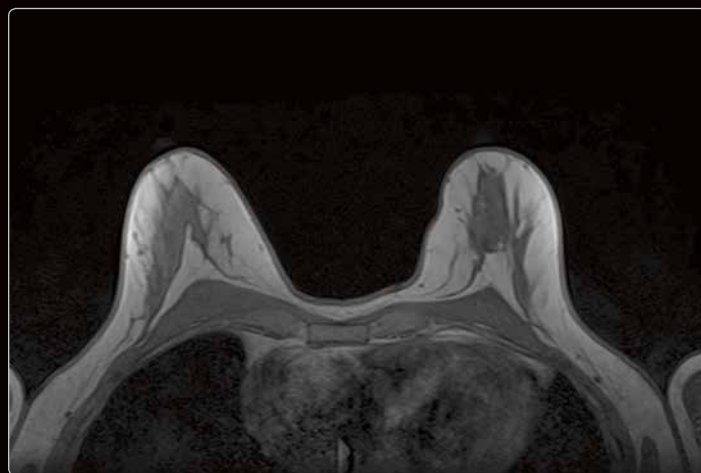
Axial 3D T1 Dynamic 1.5 mm

PATIENT HISTORY:

Histologically confirmed ductal carcinoma in situ of the right breast (G3, poorly differentiated). Further examination requested by the patient.

RESULTS:

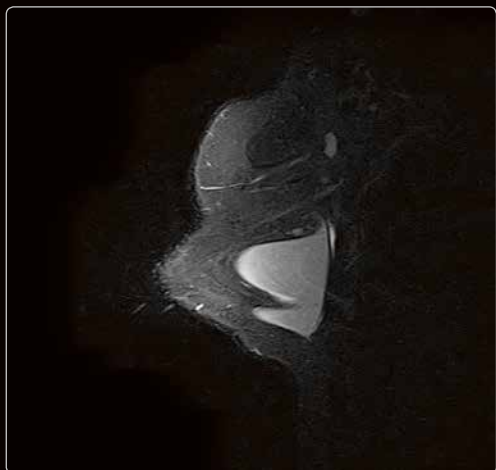
Suspicious area in the outer upper quadrant of the right breast compatible with the DCIS. No suspicious lesions observed in the left breast.



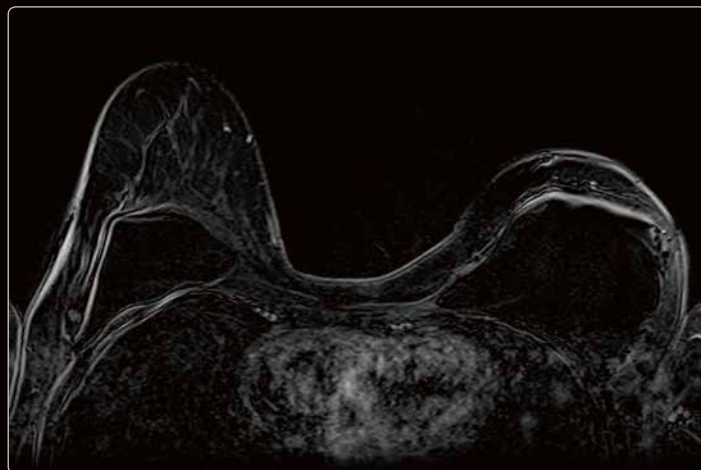Axial 3D T1 pre-contrast 1.5 mm

Breast Implants, Carcinoma Follow-Up

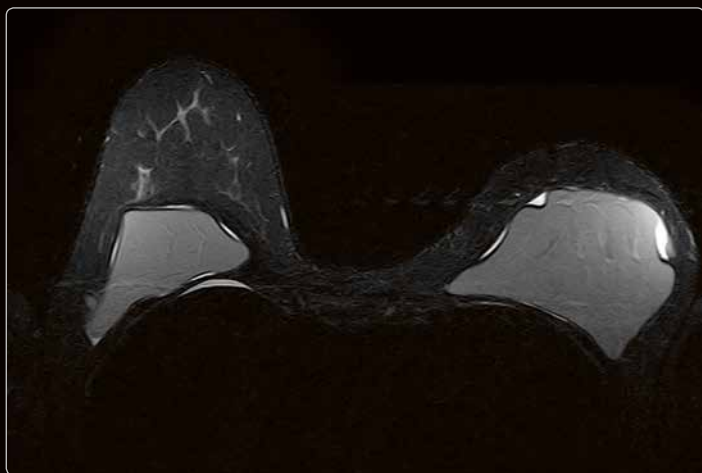
CASE 5



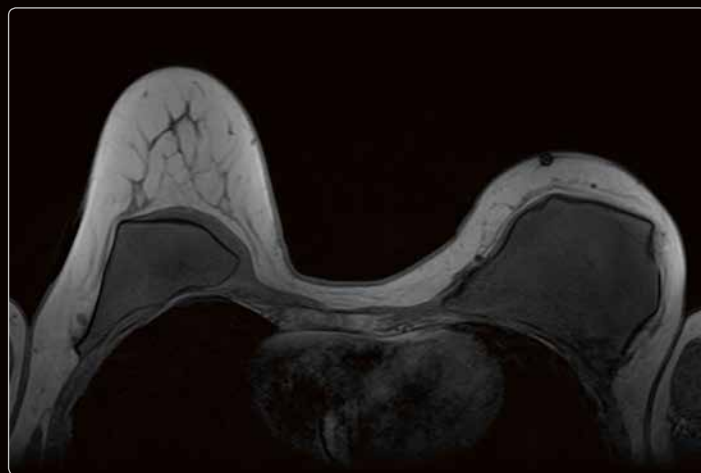
Sagittal STIR Right 1.5 mm



Axial 3D T1 Dynamic Subtraction 1.5 mm



Axial STIR 1.5 mm



Axial 3D T1 pre-contrast 1.5 mm

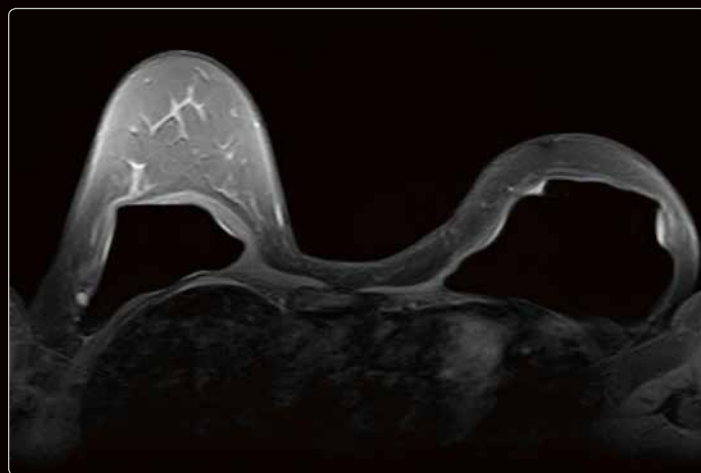
PATIENT HISTORY:

History of breast cancer left in 2003, post latissimus-dorsi-flap reconstruction followed by breast implant left, post adjustment of the right breast implant.

RESULTS:

Status post cancer left, no sign of recurrence or a secondary carcinoma.

No leakage of the breast implants on either sides. There is a small, non-specific lymph node close to the right implant.



Axial T1 FatSat PASTA Silicone 2 mm

Vantage Elan

Canon

CANON MEDICAL SYSTEMS EUROPE B.V.

<https://eu.medical.canon>

©Canon Medical Systems Corporation 2018. All rights reserved.
Design and specifications subject to change without notice.
MCAMR0001EC 2018-06 CMSE/Printed in Europe

Canon Medical Systems Corporation meets internationally recognized standards for Quality Management System ISO 9001, ISO 13485.
Canon Medical Systems Corporation meets the Environmental Management System standard ISO 14001.

Vantage Elan, M-Power, Pianissimo, Delayracker, JET and Made for Life are trademarks of Canon Medical Systems Corporation.

Disclaimer: Some features presented in this brochure may not be commercially available on all systems shown or may require the purchase of additional options. Please contact your local Canon Medical Systems representative for details.

Made For life